

A novel method of surgical management of Rockwood type III-V acromioclavicular joint injuries

S.B. Deshpande, A.S. Munde* and N.P. Naik

Department of Orthopaedics, Bharati Vidyapeeth Medical College and Hospital, Sangli Miraj Road, Vijaynagar, Sangli-416414, Maharashtra, India

Abstract: *Aims and objectives:* To assess the functional outcome of Rockwood type III-V acute acromioclavicular joint injuries. *Background:* Acromioclavicular joint injuries occur most commonly in active or athletic young adults. Treatment of acromioclavicular separations has been a subject of debate. In general, types I and II injuries are treated non-operatively in the acute setting and types III - VI injuries generally require surgical repair. A new method of surgical treatment using mersilene tape for ligament reconstruction and its outcome is described in present study. *Materials and methods:* A longitudinal study was conducted among ten patients with mean age of 37.25 years (range 30-45 years) with Rockwood Grade III-V Acromioclavicular joint injuries of less than 2 weeks duration were treated with reconstruction of acromioclavicular ligament and coracoclavicular ligament using mersilene tape from June 2011 to June 2013. The assessment of outcome was done in follow-up visits by anteroposterior radiographs and the clinical outcomes were assessed using Constant shoulder Score (CS) and cross-arm test. *Results:* Mean Constant Score was 93.1 in the operated shoulder and 95.9 in the normal shoulder ($p = 0.06$). The AC joint was clinically stable with satisfactory range of movements. *Conclusions:* Reconstruction of the acromioclavicular ligament and the coracoclavicular ligament using mersilene tape can be advocated for acute and displaced acromioclavicular joint injuries.

Keywords: Acromioclavicular joint injuries, Acromioclavicular ligament and Coracoclavicular ligament reconstruction, mersilene tape.

Introduction

Injuries in and around the shoulder, including acromioclavicular joint injuries, occur most commonly in active or athletic young adults. Proper knowledge of the different problems and treatment options for shoulder disorders is necessary to help patients to return to their preinjury state.

Acromioclavicular joint injuries are often seen after two wheeler wrecks, contact sports, and car accidents. The acromioclavicular joint is located at the top of the shoulder where the acromion process and the clavicle meet to form a joint. Several ligaments surround this joint, and depending on the severity of the injury, a person may tear one or all of the ligaments. Torn ligaments lead to acromioclavicular joint sprains and separations [1].

Injury to the acromioclavicular joint may injure the cartilage within the joint and can later cause arthritis of the acromioclavicular joint. Treatment

of acromioclavicular separations has been a subject of debate. In general, types I and II injuries are treated nonoperatively in the acute setting, and types IV, V, and VI injuries generally require surgical repair. However, reaching a consensus regarding the optimal management of acute type III injuries has been difficult.

Material and Methods

A longitudinal (follow up) study was conducted from the period of June 2011 to June 2013, 17 patients had surgery for AC joint injuries. Of 17 patients, 10 participated in a follow-up visit after a mean of 13 months (range 10–15 months). The rest 7 patients did not turn up for the follow-up visit. Patient and injury characteristics are shown in Table 1.

Ten patients with mean age of 37.25 years (range 30–45 years) with Rockwood Grade III-V Acromioclavicular joint injuries of less than 2 weeks duration were evaluated and

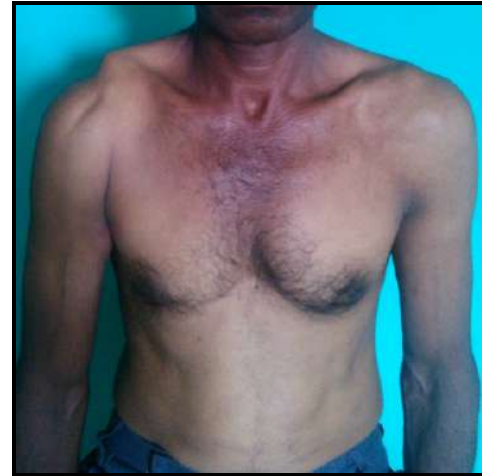treated with reconstruction of acromioclavicular ligament and coracoclavicular ligament using mersilene tape [2-4]. The outcomes were assessed using Constant shoulder Score (CS), cross-arm test and stability of the AC joint.

Table-1: Patient and injury characteristics in 10 patients treated surgically for AC joint injuries with reconstruction of acromioclavicular ligament and coracoclavicular ligament using mersilene tape	
Male/Female	7/3
Injured side Right/left	7/3
Dominance Right/left	9/1
Mechanism of primary injury Fall on outstretched hand Sport Road Traffic accident	4 0 6
Rockwood type in primary radiographs III IV V	4 1 5
Mean age at time of injury, years (range)	37.25 (30–45)
Mean duration since time of injury, days (range)	12 (9–15)

Patient Evaluation: AC joint injuries are often diagnosed by history and physical exam. We appreciated the visual deformity, swelling or ecchymosis, and palpated for tenderness over the AC joint and lateral clavicle (fig. 1). Range of motion of the shoulder was limited to pain and suggest injury. We determined the instability in the vertical or horizontal planes. On the physical exam, the “piano key” sign, which is considered positive when the distal clavicle appears mobile to axial pressure [5].

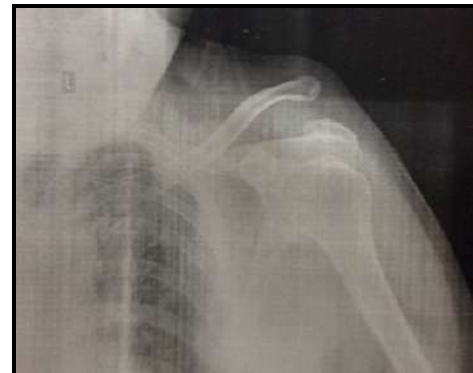Provocative testing for this injury includes the use of the cross arm adduction of the shoulder, which was done by elevating the arm to 90° and adducting the arm across the chest with the elbow flexed; this will elicit pain with an AC joint injury.

Figure-1: Clinical picture of right AC joint injury



Imaging: Imaging of the AC joint was done using anteroposterior view of the affected shoulder (fig. 2).

Figure-2: Plain radiograph of left shoulder joint in AP view showing grade V left AC joint injury.



Surgical technique: Under a suitable anaesthesia patient given supine position with a sand bag beneath the scapula of the operating side. Surgical marking done using a sterile surgical marker (fig. 3). Transverse incision taken over lateral 2/3rd of clavicle extending upto the acromion lateral tip. Lateral end of clavicle exposed by elevating deltoid muscle subperiosteally and the acromioclavicular joint is exposed (fig. 4). Coracoid process is identified after blunt dissection. Two holes made in clavicle, one hole at conoid tubercle and one hole at trapezoid ridge. Mersilene tape passed under coracoid process and then passed through these holes and tied over clavicle to correct superior displacement and to replicate the anatomy (fig. 5). Two holes made on either

side of acromioclavicular joint in antero-posterior direction. Mersilene tape passed across joint to tie knot anteriorly to hold anteroposterior displacement (fig. 6). Closure of capsule was done using 2-0 vicryl; rest of the closure and suturing done in layers.

Figure-3: Surgical marking done using sterile surgical marker.

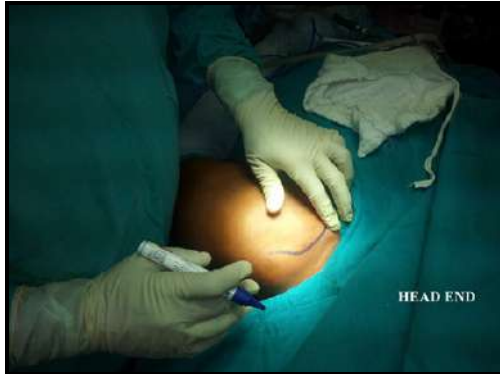

Figure-4: Left AC joint exposed.

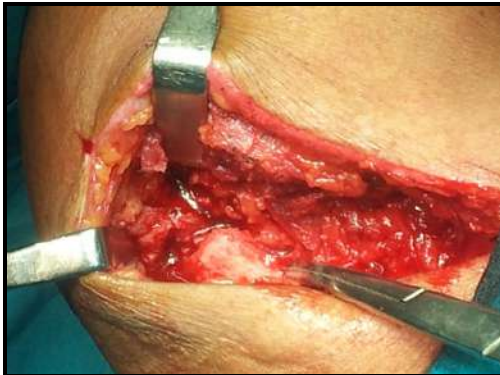


Figure-5: Mersilene tape passed under left coracoid process and then passed through the holes and tied over clavicle to correct superior displacement.

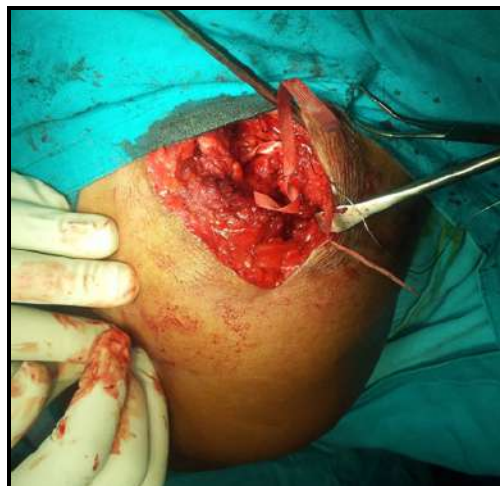
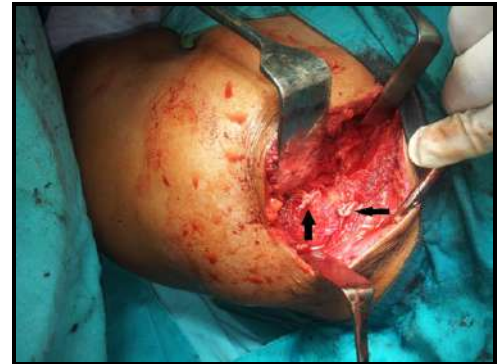
Figure-6: Mersilene tape passed across left AC joint to tie knot anteriorly to hold anteroposterior displacement.



The patients were given cuff and collar pouch postoperatively. Early pendulum exercises were started with overhead abduction started after 3 weeks. The mean final follow-up was 13 months (range 10-15 months).

The outcomes were Constant shoulder Score (CS), cross-arm test and clinical stability of the AC joint. From anteroposterior (AP) radiographs, we evaluated alignment of the AC joint, AC joint osteoarthritis, osteolysis of the lateral clavicle, and possible complications.

Statistics: The CS between the operated and normal shoulder was analyzed by unpaired t-test. There is no statistically significant difference in mean constant shoulder score of patients in post operated injured shoulder and normal shoulder ($p = 0.06$).

Postoperative Rehabilitation: Postoperative rehabilitation after acute reconstruction should consist of sling use for 3 to 4 weeks while beginning gentle range of motion in weeks 1 to 3. Isometric strengthening exercises can be started after 4 weeks while the patient is in the sling as well as after the sling is discontinued; emphasis should be placed on strengthening the scapula stabilizers. Six weeks is the earliest time point that unsupported arm range of motion should be performed in order to allow biological healing [6-8].

Full strengthening can begin approximately 12 weeks postoperatively, and the patient may return to all activities at 4 to 6 months.

Results

At the final follow up all the patients had satisfactory results in terms of pain, cosmetic correction and movements and strength of the shoulder (fig. 7) in a mean duration of 4 months (range 3-5 months) with the mean Constant Shoulder Score was 93.1 for the operated shoulder and 95.9 for the normal shoulder (p =

0.06). The AC joint was clinically stable at follow-up. On the operated side, the cross-arm test was positive in 1 patient. The results are shown in Table 2.

In the radiographs (anteroposterior view) the AC joint was in normal alignment (fig. 8) in all the patients till the mean final follow up of 13 months.

Table-2: Clinical outcomes for AC joint injuries after a mean of 13 months in the 10 patients treated surgically with reconstruction of acromioclavicular ligament and coracoclavicular ligament using mersilene tape.

Patient No.	Operated shoulder with CS	Normal shoulder with CS	Cross-arm test	AC Joint clinically
I	Right CS = 94	Left CS = 96	Negative	Stable
II	Right CS = 96	Left CS = 98	Negative	Stable
III	Right CS = 95	Left CS = 98	Negative	Stable
IV	Right CS = 96	Left CS = 98	Negative	Stable
V	Left CS = 95	Right CS = 98	Negative	Stable
VI	Right CS = 87	Left CS = 90	Positive	Stable
VII	Right CS = 89	Left CS = 90	Negative	Stable
VIII	Left CS = 92	Right CS = 95	Negative	Stable
IX	Left CS = 92	Right CS = 98	Negative	Stable
X	Right CS = 95	Left CS = 98	Negative	Stable
Mean	93.1	95.9		
sd	3.071373	3.28126		
unpaired t test	1.97			
p value	0.06			

AC = acromioclavicular. CS = Constant shoulder Score. sd = standard deviation

Figure-7: Clinical pictures after 6 weeks.

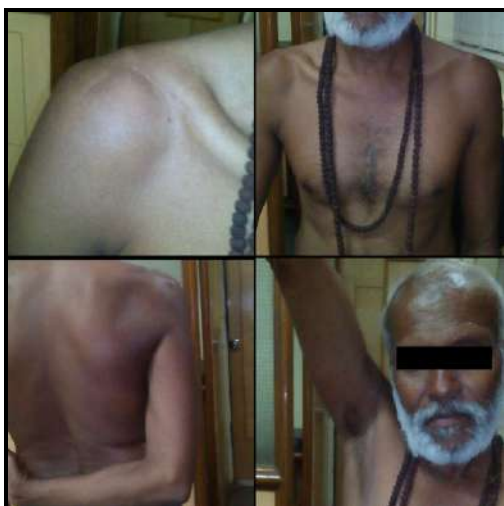
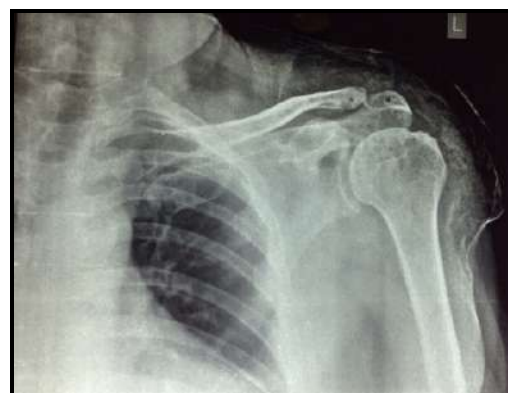
Figure-8: Plain radiograph of left shoulder joint in AP view showing normal alignment of post operated left AC joint.



Discussion

Sometimes conservative treatment of AC joint injuries is unsuccessful, or results of surgery are undesirable. Consequences may be persistent pain and insufficiency in the shoulder region, inability to perform overhead activities, and a repeated sense of instability or weakness.

McConnell AJ, Yoo DJ, Zdero R, et al [2] in their extensive study over cadaveric specimens were tested using three different methods of fixation used in acute disruption of the acromio-clavicular (AC) joint-namely, the coraco-clavicular Bosworth screw (CC Screw), a coraco-clavicular sling of Mersilene #5 tape (CC Sling), and a Hook Plate-were compared to baseline to see which could most closely replicate the stiffness of healthy cadaveric AC specimens (Intact). They concluded that the coracoclavicular Sling using mersilene tape was significantly less stiff than the intact joint or the other methods of fixation. But in their studies they used only the coracoclavicular sling whereas in our study we have used mersilene tape as a sling for both coracoclavicular and acromioclavicular fixation in acute cases, so as to maintain the anatomy of the joint.

As per Mazzocca AD, Arciero RA and Bicos J [6], the concept of increases in superior translation as well as disturbances in horizontal translation with injuries to the AC joint and ligaments were discussed.

Walz L, Salzman GM, Fabbro T, et al [3] in a biomechanical study for the acromioclavicular joint dislocations using 2 TightRope devices concluded that the anatomic reconstruction of the AC joint using TightRope was a stable and functional anatomic reconstruction procedure. The reconstruction technique led to favorable in vitro results with equal or even higher forces than native ligaments.

Joe F de Beer, Karin S van Rooyen, Deepak N Bhatia [4] discussed about Scapular Malpositioning and Rotatory Instability of the scapula in chronic AC joint dislocation which were treated with the modified Weaver-Dunn procedure in their study. The purpose of this procedure which reconstructed both the AC ligament and CC ligament is to not only realign the AC joint but also realign the shoulder blade to

take the tension off the nerves of the brachial plexus. This realignment of the shoulder blade relieves the traction on the nerves and cures the symptoms in the arm.

Olaf Rolf, Andreas Hann von Weyhern, Alexander Ewers, Dirk Boehm, Frank Gohike [7] in a retrospective study the results of early AC joint reconstruction were compared with the results of delayed reconstruction in patients who were first treated conservatively and failed after some time. A comparison of the overall results revealed a statistically significant better outcome in the early reconstruction group, regarding the Constant score, the degree of AC joint reduction, numbers of complications and patient's satisfaction.

Beitzel K, Obopilwe E, Apostolakos J, Cote MP, Russell RP, Charette R, Singh H, Arciero RA, Imhoff AB, Mazzocca AD [8] compared the modifications of previously published methods for direct AC reconstruction in addition to a CC reconstruction. The hypothesis was that there would be significant differences within the variations of surgical reconstructions. They concluded that an anatomic repair should address both the CC ligaments and the AC ligaments to control the optimal physiologic function (translation and rotation).

In our study, all patients were treated in early phase with reconstruction of acromioclavicular ligament and coracoclavicular ligament using mersilene tape as to correct the antero-posterior displacements and the superior-inferior displacements respectively. At follow-up, clinical outcomes were satisfactory to good in regards to both the displacements. The rates of complications were very low till the mean final follow up of 13 months.

Our patients scored better in function, disability, pain, and satisfaction. The aim of reconstructive surgery is to eliminate pain and discomfort by stabilizing the AC joint and maintaining or even improving shoulder function. These fundamental aims were achieved. There was no altered anatomical relations, no high torsional forces in the lateral

clavicle, and there was no tunnel widening or osteolysis noted till the mean final follow up of 13 months which gave the results for a good stabilization with satisfactory range of movements. The radiological findings were satisfactory to good with satisfactory range of movements. Because of the importance of the AC ligament and CC ligament for AC joint stability, we recommend reconstruction of the acromioclavicular ligament and the coracoclavicular ligaments using mersilene tape in acute acromioclavicular joint injuries.

Conclusion

Reconstruction of the acromioclavicular ligament and the coracoclavicular ligaments using mersilene tape can be advocated for acute and displaced acromioclavicular joint injuries. The success rate of this procedure has been very high with early and full return to pre-injury activities.

References

1. Rockwood CA Jr, Green DP, Bucholz RW, Heckman JD. Fractures in Adults. 4th ed. Philadelphia, Pa: Lippincott-Raven; 1996; [Chapter 20] pp. 134–1431.
2. McConnell AJ, Yoo DJ, Zdero R, et al. Methods of operative fixation of the acromioclavicular joint: a biomechanical comparison. *J Orthop Trauma*. 2007; 21(4):248-53.
3. Walz L, Salzman GM, Fabbro T, et al. The anatomic reconstruction of acromioclavicular joint dislocations using 2 Tight Rope devices: a biomechanical study. *Am J Sports Med*. 2008; 36(12):2398-406.
4. Joe F de Beer, Karin S van Rooyen, Deepak N Bhatia. The Cape shoulder institute - Shoulder Problems/ Acromioclavicular (AC) Joint Dislocations publisher Dr Joe F de Beer & Associate; 2010 treated chronic AC joint dislocations using a “modified Weaver-Dunn” procedure. 2010.
5. Fraser-Moodie JA, Shortt NL, Robinson CM. Injuries to the acromioclavicular joint. *J Bone Joint Surg Br*. 2008; 90(6):697-707.
6. Mazzocca AD, Arciero RA, Bicos J. Evaluation and treatment of acromioclavicular joint injuries. *Am J Sports Med*. 2007; 35(2):316-29.
7. Olaf Rolf, Andreas Hann von Weyhern, Alexander Ewers, Dirk Boehm, Frank Gohike. Acromioclavicular dislocation Rockwood III–V: results of early versus delayed surgical treatment. *Archives of Orthopedic and Trauma Surgery* 2008; 128(10):1153-1157.
8. Beitzel K, Obopilwe E, Apostolakis J, Cote MP, Russell RP, Charette R, Singh H, Arciero RA, Imhoff AB, Mazzocca AD. Rotational and translational stability of different methods for direct acromioclavicular ligament repair in anatomic acromioclavicular joint reconstruction. *Am J Sports Med*. 2014; 42(9):2141-8.

*All correspondences to: Dr. Amit Munde, Room no-26, PG resident Hostel, 3rd Floor, Bharati Vidyapeeth Medical College and Hospital, Sangli Miraj Road, Vijaynagar, Sangli-416414, Maharashtra, India. Email: dr.amitmunde@yahoo.com