

Tendoscopy: A novel way to look at an Enigma; Indications, Technique & Results of managing tendon pathologies in foot and ankle

Abhishek Kini¹, Amit Munde¹

Abstract

Background: Lack of consensus remains regarding management of the myriad of etiologies that affect the tendons traversing the hindfoot. Commonly affected tendons include the peroneals, flexor hallucis longus (FHL), tibialis posterior and the Achilles tendons. Tendoscopy is a largely unexplored approach in treatment of these varied causes. There is not enough international literature available on the utility of this novel technique. With this paper we aim to study the indications for tendoscopy, describe its technique and present its results.

Methods: Sixteen patients with failed conservative care for the above mentioned tendon related complaints were treated tendoscopically from June 2013 to December 2015. We detail the surgical steps to perform tendoscopy. Age, gender, timing of surgery, work & activity demands, preop & 6 months postop AOFAS hindfoot score were noted. At final followup patients were asked to rate their overall result as excellent, good, fair or poor & whether they were satisfied.

Results: Five patients had peroneal tendon, six patients had FHL, two tibialis posterior tendon and 3 Achilles tendon pathologies. 11 active high demand individuals were part of this group and all of these could resume their high demand activity by 6 to 12 weeks. AOFAS hindfoot score improved from 58.6 +/-8.9 to 81.3 +/-7.1 ($p>0.05$). All patients were satisfied with their surgical outcome.

Conclusion: Tendoscopy is a safe technique to treat the tendons traversing the hindfoot. Advantage being ability to examine longer length of tendon in a minimally invasive manner leading to low morbidity, early recovery to activities.

Introduction

Foot and ankle is a nature's marvel enabling us to move on two limbs. To enable us to attain this function, we have a structure, comprising of bones forming joints and tendons that traverse these joints to move them. Thus with overuse of these tendons, they are vulnerable to injuries, degeneration and a myriad of other pathologies which affect quality of life of common man and athletes equally. One of the hurdles for effective treatment and recovery post treatment of these pathologies is the approach to these deep-seated tendons. In the past, surgical exploration of these tendons were associated with surgical morbidity and hence, poor functional outcome. With advances in arthroscopic technique, equipment and better understanding of anatomy, use of endoscopic exploration for tendons have gained acceptance. Wertheimer first published this relatively novel tendoscopic technique in 1995 [1]. In 1997, van Dijk, Sholten and Kort

published a paper on endoscopy of the peroneal, anterior tibial and Achilles tendon sheaths, and named the technique 'tendoscopy' [2]. In current literature, there is limited evidence in support of this technique. With this paper we aim to study the indications for tendoscopy, describe its technique and present its results of commonly affected tendons of the hindfoot coming up in our practice, namely the peroneal tendons, posterior tibial (PT) tendon, flexor hallucis longus (FHL) tendon and the Achilles tendon.

Indications, Technique & Results

Sixteen patients with failed conservative care for the above mentioned tendon related complaints were treated tendoscopically from June 2013 to December 2015. The following technique was performed for individual tendons:

Peroneal tendons:

We had 5 patients with peroneal tendon pathologies who were treated tendoscopically. 4 patients had tenosynovitis with a partial tear / split in tendon. One patient had a low-lying peroneus brevis muscle belly, which was causing intrasheath impingement. They presented with pain in retrofibular groove region and on examination, had tenderness and crepitus overlying the tendon. MRI was the confirming imaging modality used. (Fig. 1) The operative technique for Peroneal tendoscopy was first described by van Dijk [3]. The patient may be placed in a lateral, anterior or prone position depending on the potential concomitant procedures planned beforehand. When peroneal tendoscopy is performed as an isolated procedure, we prefer the lateral position. A thigh tourniquet is applied and gravity inflow is used to insufflate the paratenon. Portals are made using a size 11 scalpel. We prefer making the proximal portal first. It is placed around 3 cm proximal to the lateral malleolus tip, along the course of the peroneal tendons. The distal portal is made under vision, around 2 cm distal to the malleolar tip. Portals may be changed depending on the location of the disorder. (Fig 2) The working space is limited by the fibrous tendon sheath, and rotation of the scope is needed to reach the whole span of the tendon sheath. A 1 cm skin incision is

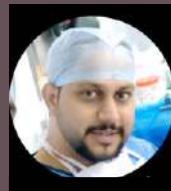¹Department of Orthopaedics, P.D.Hinduja Hospital & Medical Research Centre, Mumbai, India.

Address of Correspondence

Dr. Abhishek Kini, Dept. of Orthopaedics, PD Hinduja hospital & Medical research centre, Mahim, Mumbai, India. Email: kiniabhishek@gmail.com



Dr. Abhishek Kini



Dr. Amit Munde

© 2018 Simon et al | Asian Journal of Arthroscopy | Available on www.asianarthroscopy.com | doi:10.13107/aja.2456-1169.234

This is an Open Access article distributed under the terms of the Creative Commons Attribution Non-Commercial License (<http://creativecommons.org/licenses/by-nc/3.0/>) which permits unrestricted non-commercial use, distribution, and reproduction in any medium, provided the original work is properly cited.

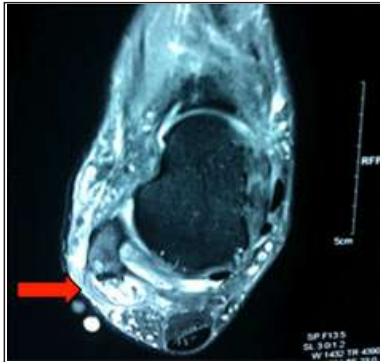


Figure 1: MRI imaging showing Peroneal tenosynovitis

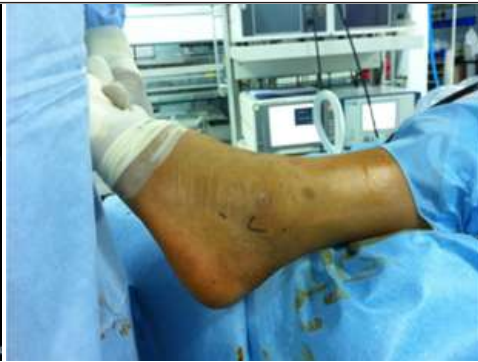

Figure 2: Peroneal tenoscopy portal markings.

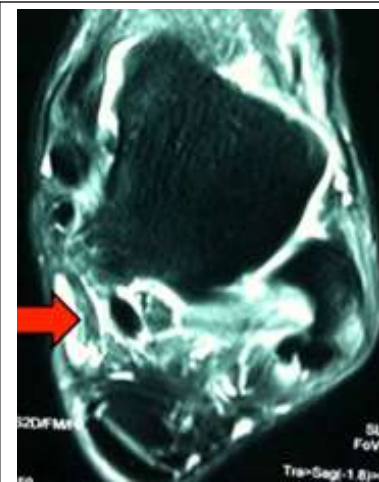


Figure 4: FHL tendon with loose ossicle and surrounding tenosynovitis.

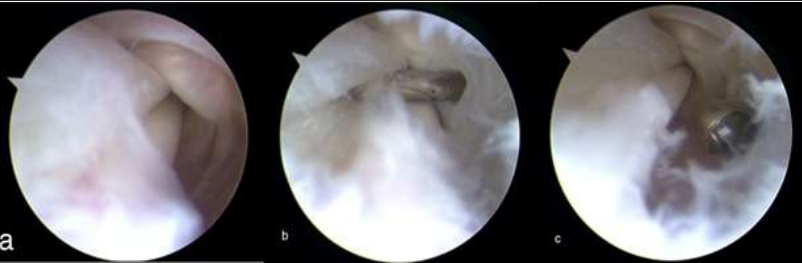

Figure 3: a: Tendoscopic view of both peroneal tendons intrasheath. b: Probe pointing out a split in Peroneus brevis tendon. c: Shaver seen post tenosynovium debridement.

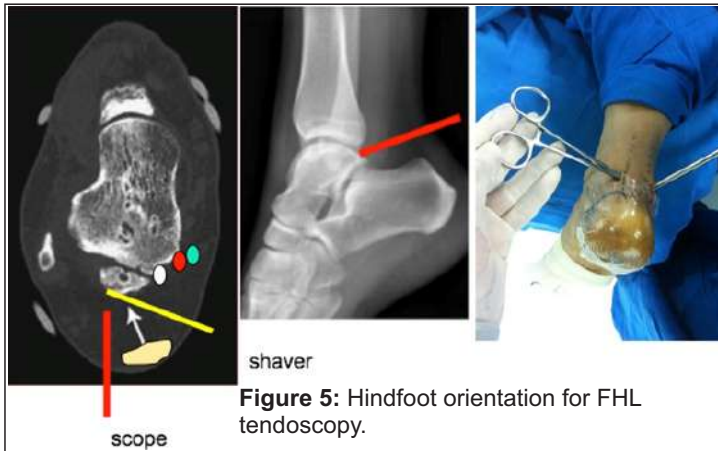

Figure 5: Hindfoot orientation for FHL tenoscopy.

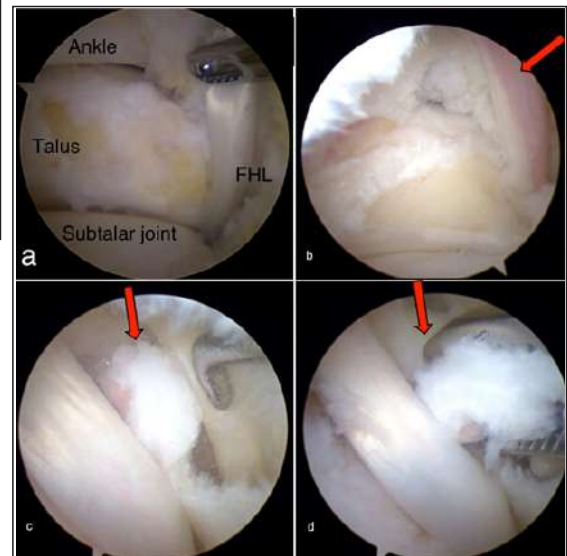


Figure 6: a: Hindfoot endoscopic picture showing the ankle and subtalar joint with FHL tendon. Area lateral to FHL is the safe area in hindfoot. b: FHL tenosynovitis. c: Loose bony ossicle in FHL sheath. d: Loose ossicle removal.

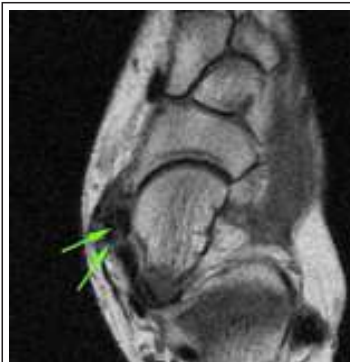


Figure 7: MR image showing Posterior Tibial tendon split.

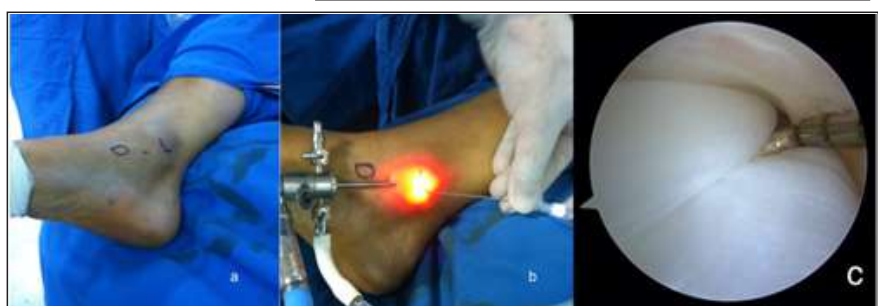

Figure 8: a: Posterior Tibial tenoscopy position & markings. b: Proximal portal taken under vision. c: PT tenoscopic view showing a split in tendon.

made over the peroneals, following the longitudinal axis of the tendons. Subcutaneous dissection is made to expose tendon sheath. The sheath is opened with a 1 cm incision along the longitudinal axis of the tendon. Proximally, with the tendons being palpable, it's easier to get into the sheath as

compared to distally. A blunt trocar is first used to release adhesions and create space for the scope. A 30° 2.7 mm or 4.0 mm scope is first gently introduced through the distal portal. Under direct visualization, a spinal needle is placed to locate the distal portal placement. Special care should be taken

to orientate the needle and the scalpel obliquely so as not to penetrate and damage the tendons. A probe is introduced through the proximal portal to release any remaining fibrotic tissue around the tendons. Inspection includes ruling out a peroneus quartus tendon, intrasheath subluxation and

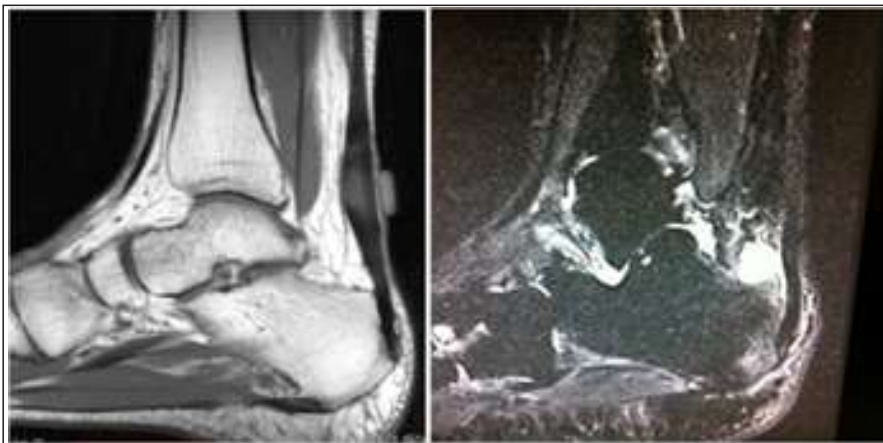

Figure 9: a: Non insertional tendinosis of Achilles tendon, b: Insertional tendinosis Achilles tendon with retrocalcaneal bursitis.

longitudinal tears. A shaver system is introduced through the proximal portal to debride hypertrophic synovium and fibrosis. (Fig.3) Small tendon nodules can also be debrided if present. A burr may be used through the proximal portal for the deepening of the malleolar groove in cases of peroneal dislocation. Some peripheral tears may be debrided via a tendoscopic approach. Portals are closed with absorbable sutures and a compression bandage is left for 7-8 days till suture removal. As an isolated procedure for synovitis, the patient is allowed to bear weight as tolerated with the use of crutches. Active range-of-motion exercises are recommended from the first post-operative week. Return to non-impact sports is encouraged at three weeks and return-to-play for impact sports is resumed at six to eight weeks from surgery. In the case of a longitudinal tear repair, post-operative recommendations are dependent on the extent of the repair.

Flexor hallucis longus (FHL) tendon:

We had six patients with FHL tendon pathologies, 4 had bony posterior impingement, 1 had loose bony ossicle and 1 had a low-lying FHL muscle belly leading to soft tissue impingement in the

osseotendinous canal. They presented with pain in medial hindfoot region and on examination, had tenderness and crepitus overlying the tendon. MRI was diagnostic imaging modality and it confirmed above pathologies. (Fig. 4) The patient is in the prone position with a thigh tourniquet to provide a bloodless operative field. A 4.0-mm 30° arthroscope (Dyonics; Smith & Nephew, MA) is used for this procedure.

Portal Placement

Posterior ankle tendoscopy 4 is performed with the posteromedial (PM) and posterolateral (PL) portals. The posterolateral portal is located on the lateral side of the Achilles tendon in line with the distal end of Fibula. The posteromedial portal is located in line with the posterolateral portal on the medial side of tendoachilles[5,6]. Five-millimeter skin incisions are made at the portal sites, the subcutaneous tissue is bluntly dissected by a hemostat, and the investing fascia is penetrated by the tip of the hemostat. (Fig.5) PL portal is the safe portal while PM portal needs careful attention with the neurovascular bundle lying in close proximity. The posterolateral portal is the viewing portal. The adipose tissue of the

posterior ankle is debrided by an arthroscopic shaver (Dyonics; Smith & Nephew) through the posteromedial portal, starting from the lateral side of the posterior ankle, until the FHL tendon is exposed. The FHL tendon can be confirmed as it moves with plantar flexion and dorsiflexion of the great toe. Area lateral to FHL tendon is the safe area of hindfoot and hence, the FHL tendon acts like a lighthouse of the hindfoot. The FHL tendon is traced proximally to identify the FHL muscle. The fascia over the FHL muscle is released by an arthroscopic shaver and arthroscopic scissors (Dyonics; Smith & Nephew) through the posteromedial portal. (Fig.6) Release of the fascia should be proximal enough to allow subsequent release of the FHL muscle. The texture of the FHL muscle is assessed by an arthroscopic probe. The fibrosis may only be limited to the deep surface of the FHL muscle adherent to the distal tibia. After complete examination of FHL tendon & its sheath, the concerned pathology is addressed, i.e. low lying muscle belly is debrided with a shaver & loose ossicle is removed. Portals are closed with absorbable sutures and a compression bandage is left 7-8 days till suture removal. Active range-of-motion exercises are recommended from the first post-operative week. Return to non-impact sports is encouraged at three weeks and return-to-play for impact sports is resumed at six to eight weeks from surgery.

Posterior Tibial tendon:

We had two patients with Posterior tibial tendon (PTT) split with tenosynovitis. They presented with pain in medial hindfoot region and on examination, had swelling, tenderness and crepitus overlying the tendon. Both had valgus hindfoot alignment. MRI was diagnostic imaging modality and it confirmed above pathology. (Fig. 7) With the patient supine, references are marked on the skin to identify the navicular, the PTT, the medial malleolus and the two main portals (Fig 8). Active inversion and eversion of the foot before anaesthesia may facilitate the identification of anatomical landmarks. It is recommended to use a 2.7 mm scope with an inclination angle of 30° to facilitate access to the tendon, but a 4.0 mm arthroscope may also be used for most PTT tendoscopies. A thigh tourniquet is applied and gravity inflow is used to insufflate the paratenon. Portals are made using a size 11 scalpel. Two portals are usually recommended, between 2 cm and 2.5 cm proximal and distal to the tip of the

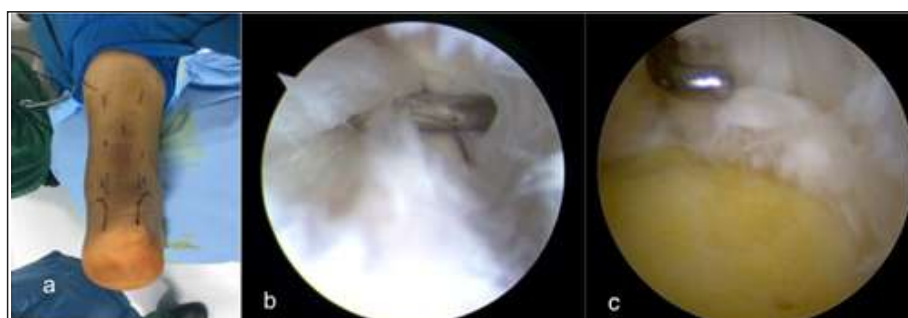

Figure 10: a: TendoAchilles tendoscopy portals, b: Non Insertional tendinosis debridement, c: Insertional tendoachilles decompression.

posteromedial edge of the medial malleolus. The distal portal is created first. A 1 cm skin incision is made over the PTT, halfway between the medial malleolus and the navicular, following the longitudinal axis of the tendon. Subcutaneous dissection is made to expose the PTT sheath. The sheath is opened with a 1 cm incision along the longitudinal axis of the tendon. The arthroscope with blunt trocar is introduced and the tendon sheath is inspected without saline to gain information on synovitis. Following 'dry inspection', the sheath is filled with saline. While inverting the foot, the arthroscope is advanced carefully to inspect the complete PT tendon up to the vinculum, at around 4 cm proximal to the tip of the medial malleolus. Under direct visualisation, the insertion of a spinal needle helps to place the skin incision for the proximal portal around 3 cm proximal to the tip of the medial malleolus. Special care should be taken to orientate the needle and the scalpel obliquely so as not to penetrate and damage the tendon. With the arthroscope in the distal portal, a blunt probe and a shaver system may be introduced through the proximal portal (Fig 8c). The complete tendon sheath may be inspected by rotating the scope around the tendon. Synovitis or partial tears may be debrided with a shaver. At the end of the procedure, portals are closed with absorbable sutures. A compression bandage is recommended for 7-8 days till suture removal. Weight-bearing is allowed as tolerated immediately after surgery (provided associated procedures do not require the patient to be non-weight-bearing, i.e. calcaneal osteotomy), and active inversion and eversion movements are encouraged.

Achilles tendoscopy:

We had 2 patients of non insertional Achilles tendinopathy and one patient of insertional tendinosis with retrocalcaneal bursitis. Patient presented with pain, especially on first getting up from bed/chair and on examination had thickening of involved tendon. MRI was diagnostic modality of choice. (Fig.9) The operative technique for Achilles tendoscopy was developed by van Dijk et al[2] & later decribed in detail by Steenstra et al[7]. The patient is placed prone with a tourniquet on the thigh, and the foot out of the operating table to allow the surgeon to dorsiflex and plantarflex the ankle joint. Portals are made using a size 11 scalpel. The distal portal is made on the lateral border of the tendon,

around 3-4 cm distal to the thickening of the Achilles in non insertional tendinopathy. The proximal portal is made on the medial border of the tendon, around 3-4 cm proximal to the thickening to allow for around 15 cm of length to visualise and work along the tendon. Multiple similar portals can be made to approach the desired area of tendon (Fig.10a). The distal lateral portal is placed first. A blunt trocar is first used through the distal portal and a 2.7 mm or 4.0 mm scope is used to release adhesions in the paratenon space by repeatedly passing it around the Achilles. This manoeuvre, together with plantarflexion of the ankle joint, allows for the easier introduction of a 30° 2.7 mm or 4.0 mm scope through the lateral distal portal and the probe and shaver through the proximal portal. Once the scope is introduced through the distal portal, gravity inflow is used to insufflate the paratenon. Under direct visualisation, a spinal needle is placed to locate the second portal placement. A probe is introduced through the proximal medial portal to release any remaining fibrotic tissue binding the tendon (Fig.10b). A shaver system is introduced through the proximal portal to debride hypertrophic fibrosis. If present, plantaris tendon is released from the Achilles. Small tendon nodules may be debrided if present. For insertional tendinosis and retrocalcaneal bursitis, portals are closer to the tendon insertion on either side of the tendon in order to access the Haglund's bump. This bump is shaved off using an acrominiser (Dyonics, SnN) and the surrounding bursae is excised. The insertional tendon is decompressed adequately and this promotes healing. (Fig.10c) Portals are closed with absorbable sutures and a compression bandage is left for 7-8 days till suture removal. The patient is allowed to bear weight, as tolerated, with the use of crutches and active range-of-motion exercises are encouraged from the first post-operative week. Eccentric exercises are introduced at around the third post-operative week. Return to non-impact sports is encouraged at three weeks and return-to-play for impact sports is resumed at six to eight weeks after surgery We had 7 females and 9 males in this series with mean age of 28years (16-54)[11]. active high demand individuals (5 sportspersons, 3 competitive runners & 3 dancers) were part of this group and all of these could resume their high demand activity by 6 to 12 weeks. AOFAS hindfoot score improved from 58.6 +/-8.9 to 81.3 +/-7.1 (p>0.05). 12 patients

reported excellent outcomes, 3 patients (1 each of Peroneal, FHL & PTT tendoscopy) reported good outcome and 1 patient of peroneal tendoscopy, whose partial split was tendoscopically debrided, developed intra-sheath subluxation, reported fair outcome. All patients were satisfied with their surgical outcome. 2 patients had portal hypersensitivity, which improved with local management in 6 months.

Discussion:

Advances in arthroscopic and endoscopic techniques have continued to expand indications for foot and ankle tendoscopy. However, there is little quality evidence-based data in the current literature to support routine use of tendoscopies. Several retrospective reviews have reported on the outcomes of endoscopic treatment for a variety of indications. The diagnostic utility of this technique has become more widely recognized, although for selected indications. This article reports authors' experience in treating tendon pathologies with an arthroscopic procedure. Peroneal tendoscopy is the most commonly done tendoscopy due to its ease of access. Indications for open surgery of the peroneal tendons are now covered by tendoscopy, except for the repair of extensive longitudinal tears. Retrofibular pain, tenosynovitis, subluxation or dislocation, intrasheath subluxation, partial tears, impingement of peroneus longus at the peroneal tubercle, post-operative adhesions and scarring, and resection of a peroneus quartus tendon or a bifid peroneus brevis or a low-lying peroneal muscle belly are common indications which can be accessed tendoscopically. Patients with peroneal adhesions and tenosynovitis seem to benefit most from tendoscopy[8,9]. Vega et al[10] reported complete relief of pain in 62.5% in 24 patients with partial ruptures of the peroneals. However, three of these patients with tears did not experience changes in symptoms after tendoscopic debridement. These authors also reported excellent results in seven patients of their series who had tendon instability and were treated with tendoscopic deepening of the peroneal groove for tendon subluxation, and in six patients with intrasheath subluxation of the peroneal tendons. Scholten et al[11] had described the technique for deepening the fibular groove for the treatment of peroneal dislocation. Guillo and Calder [12] had excellent results in seven patients with dislocation of peroneal tendons

after tendoscopic reconstruction. Michels et al reported on the endoscopic treatment of intrasheath peroneal subluxation with excellent results in three patients[13]. We did not have any case with peroneal tendon instability in our series, but as we expand our skills in tendoscopy, we are confident of treating these patients endoscopically. All 5 of our patients with tears & impingement did well postoperatively and were satisfied with the procedure. Overall, level IV and V studies on peroneal tendoscopy reported good to excellent results in most patients, with few complications[14]. However, the most common indication for peroneal surgery—longitudinal tears—still needs an open approach for the repair, but the size of incision reduces significantly as the endoscopic evaluation give us an confirm idea of the extent of tear which needs to be repaired. Flexor hallucis longus tendon pathologies include symptomatic fibrous adhesion of distal FHL muscle to distal tibia, bony posterior impingement, loose bodies, low lying muscle belly causing soft tissue impingement. An arthroscopic release of the tendon was performed with removal of an os trigonum or Stieda's process when present. There are relatively few reports of arthroscopic release of this tendon along its fibro-osseous tunnel behind the medial malleolus. Van Dijk[15] presented the results of 63 procedures with arthroscopic treatment of posterior ankle impingement, including debridement, os trigonum removal, and FHL release. He had 80% of good and excellent results with rapid return to work (3 weeks) and to sport (9 weeks). He stated that these results were better than with open treatment. Lui published technical notes on foot and ankle arthroscopy and reported that this procedure is feasible[16]. Conversely, in a cadaveric study, Keeling and Guyton concluded that arthroscopic release would be more risky than an open procedure[17]. Four patients of our series with posterior bony impingement, recovered satisfactorily to resume their high demand activities by 6 weeks, the rest (with loose ossicle and low lying muscle belly) could resume by 8 weeks. Tendoscopy for Posterior tibial tendon (PTT) are rare in our practice as the patients rarely visit a physician in stage 1 of adult acquired flat foot, i.e. stage of tenosynovitis. Any later presentation, needing a complete flat foot reconstruction, goes for an open debridement of the PT tendon. Following the initial description by Wertheimer et al[1], the

first series of patients that underwent PTT tendoscopy was presented by van Dijk et al[18]. Van Dijk et al reported very elegantly on the surgical technique and on the outcome of 16 patients with posteromedial pain on palpation over the PTT. Although with heterogeneous indications (diagnostic procedures in five patients), most patients were free of pain and showed no complications. Special attention was focused on the pathological thickening of the free edge of the vinculum. The vinculum was usually located some 4 cm proximal to the posterior edge of the medial malleolus and connected the tendon to the tendon sheath. Patients presenting with pain located around the vinculum region seemed to benefit from tendoscopic resection. Bulstra et al published their experience with a series of 33 patients who underwent tendoscopy with good results for pathologic vincula and rheumatoid arthritis, but poor results for adhesiolysis, all with a low complication rate[19]. Chow et al reported on a series of six patients with synovectomy due to stage I PTT dysfunction with no complications and no progression to stage II PTT dysfunction[20]. Khazen and Khazen performed PTT tendoscopies in nine patients with stage I PTT dysfunction, with pain improvement in eight patients[21]. Lui reported on the use of endoscopic-assisted PTT reconstruction for stage II dysfunction[22]. Hua et al published a retrospective review of a series of 15 patients with PTT disorders with a posterior arthroscopic approach with no neurovascular complications and just one patient with a poor outcome[23]. Overall, the best outcome was registered for the resection of pathological vincula, with more discrete results for adhesiolysis[24]. There is no clear explanation for pain resolution following tendoscopic vinculum resection. Further studies are needed to know the real significance of the PTT vinculum. Non-insertional Achilles tendinopathy and peritendinopathy are the most frequent indications for Achilles tendoscopy. The origin of pain in non-insertional Achilles tendinopathy has not yet been clarified. Neovascularisation and neoinnervation from surrounding tissues are actually the more accepted theories about the aetiology of pain[25]. Achilles tendoscopy seems to be an adequate technique to allow for adhesion release and the destruction of neovessels and neonerves while preserving skin integrity. A probe or a shaver may be used to obtain

adhesiolysis in chronic Achilles tendinopathy. Most indications for open surgery of the Achilles tendon are now theoretically covered by tendoscopy with lower morbidity and, in particular, fewer wound problems. Tendoscopy may also play a role in assisting the repair of acute Achilles tendon ruptures. Other indications for Achilles tendoscopy include retrocalcaneal bursitis (endoscopic calcaneoplasty), plantaris tendon augmentation and flexor hallucis augmentation in chronic neglected ruptures. For Achilles tendon ruptures, tendoscopy has been advocated by some authors to provide a better assessment of tendon end approximation[26]. In the scenario of the six stab incisions for a mini-invasive repair, the scope may be introduced through the central medial portal (over the tendon gap) to corroborate tendon end apposition. Halasi et al[26] prospectively studied the results of percutaneous acute Achilles rupture repair with and without tendoscopic assistance. In this level II study, endoscopy was intended to control apposition of the tendon ends. Although not statistically significant, the authors noted that they were able to get a more precise repair with the aid of tendoscopy. Maquirriain [27] presented the long-term results of Achilles tendoscopy for chronic non-insertional tendinopathy. Mean follow-up was 7.7 years (5 to 14). In total, 24 patients (27 procedures) underwent paratenon debridement and longitudinal tenotomies resulting in 96% of patients free of symptoms. Pearce et al[28]. evaluated the results of Achilles tendoscopy for non-insertional tendinopathy with division of the plantaris tendon. Almost 73% of their 11 patients were satisfied with the final outcome. Some other level IV studies (retrospective case series) reported good to excellent results when dealing with endoscopy of the Achilles tendon for non-insertional tendinopathy and acute and chronic ruptures[29-32]. Lui[33] described the treatment of chronic non-insertional Achilles tendinopathy with endoscopic Achilles debridement and flexor hallucis longus transfer. Gossage et al[34] reported the endoscopic assistance for the augmentation of a chronic Achilles tendon rupture with flexor hallucis longus tendon. There are still some limitations for tendoscopy. Extensive longitudinal tendon tears are difficult to repair endoscopically but new suture equipment will make it possible in the future. Foot and ankle tendoscopy offers advantages over open procedures; fewer

wound infections; less blood loss; smaller wounds; lower morbidity; quicker recovery; early mobilisation and function, mild post-operative pain and the possibility of being performed under local anaesthesia on an outpatient basis. Nonetheless, sufficient endoscopic skills are needed to avoid neurovascular and skin complications. Although not yet widely adopted, foot and ankle tendoscopy is gaining popularity among foot and ankle surgeons. Further research is needed in this area to have a more evidence-based approach. Tendoscopy will possibly allow for a future classification of different findings in and around foot and ankle tendons in the same way arthroscopy did. It will be important to establish which findings are physiological or pathological. Visualisation of

the tendon is only rivaled by open surgery, but with greater morbidity. To expand the use of this technique, new instruments dedicated to tendoscopy and proper surgical training in a safe environment are required. The development of new suture endoscopic materials will allow for the treatment of longitudinal tears and new gadgets will possibly allow for the harvesting of tendons whenever needed. Meanwhile, tendoscopy is becoming an important diagnostic and therapeutic tool when dealing with selected indications in foot and ankle pathology, but it will still have to wait for papers of higher levels of evidence to become the gold standard treatment for tendon pathology around the foot and ankle.

Conclusion

Tendoscopy is a safe technique to treat the tendons traversing the hindfoot. Additionally it gives us the ability to examine longer length of tendon & other structures in the hindfoot which may be pathologic in a minimally invasive manner. Tendoscopy can be performed as a day care surgery and followed by a functional post-operative treatment has the advantages of less post-operative pain, fewer complications and early recovery to activities.

Acknowledgement

Innovision Imaging, Mumbai, India for proving MR images used in this paper.

References

1. Wertheimer SJ, Weber CA, Loder BG, Calderone DR, Frascone ST. The role of endoscopy in treatment of stenosing posterior tibial tenosynovitis. *J Foot Ankle Surg* 1995;34:15-22.
2. Van Dijk CN, Sholten PE, Kort N. Tendoscopy (tendon sheath endoscopy) for overuse tendon injuries. *Oper Tech Sports Med* 1997;5:170-178.
3. Van Dijk CN, Kort N. Tendoscopy of the peroneal tendons. *Arthroscopy* 1998;14:471-78.
4. Van Dijk C.N., Scholten P.E., Krips R. A 2-portal endoscopic approach for diagnosis and treatment of posterior ankle pathology. *Arthroscopy* 2000;16:871-876.
5. Lui T.H. Flexor hallucis longus tendoscopy: A technical note. *Knee Surg Sports Traumatol Arthrosc* 2009;17:107-110.
6. Lui T.H. Endoscopic assisted flexor hallucis tendon transfer in the management of chronic rupture of Achilles tendon. *Knee Surg Sports Traumatol Arthrosc* 2007;15:1163-1166.
7. F. Steenstra and C. Niek van Dijk, "Achilles Tendo-scopy," *Foot and Ankle Clinics*, Vol. 11, No. 2, 2006, pp. 429-438.
8. Scholten PE, van Dijk CN. Tendoscopy of the peroneal tendons. *Foot Ankle Clin* 2006;11:415-420.
9. Jerosch J, Aldawoudy A. Tendoscopic management of peroneal tendon disorders. *Knee Surg Sports Traumatol Arthrosc* 2007;15:806-810.
10. Vega J, Golano P, Batista JP, Malagelada F, Pellegrino A. Tendoscopic procedure associated with peroneal tendons. *Tech Foot Ankle Surg* 2013;12:39-48.
11. Scholten PE, Breugem SJ, van Dijk CN. Tendoscopic treatment of recurrent peroneal tendon dislocation. *Knee Surg Sports Traumatol Arthrosc* 2013;21:1304-1306.
12. Guillo S, Calder JD. Treatment of recurring peroneal tendon subluxation in athletes: endoscopic repair of the retinaculum. *Foot Ankle Clin* 2013;18:293-300.
13. Michels F, Jambou S, Guillo S. Endoscopic treatment of intrasheath peroneal tendon subluxation. *Case Rep Med* 2013;274685.
14. Cychoz CC, Phisitkul P, Barg A, et al. Foot and ankle tendoscopy: evidence-based recommendations. *Arthroscopy* 2014;30:755-765.
15. Van Dijk, CN: Anterior and posterior ankle impingement. *Foot Ankle Clin North Am*. 11:663-683, 2006.
16. Keeling, JJ; Guyton, GP: Endoscopic flexor hallucis longus decompression: a cadaver study. *Foot Ankle Int*. 28:810-814, 2007.
17. Lui, TH: Arthroscopy and endoscopy of the foot and ankle: indications for new techniques. *Arthroscopy*. 23:889-902, 2007.
18. Van Dijk CN, Kort N, Scholten PE. Tendoscopy of the posterior tibial tendon. *Arthroscopy* 1997;13:692-698.
19. Bulstra GH, Olsthoorn PG, Niek van Dijk C. Tendoscopy of the posterior tibial tendon. *Foot Ankle Clin* 2006;11:421-427, viii.
20. Chow HT, Chan KB, Lui TH. Tendoscopic debridement for stage I posterior tibial tendon dysfunction. *Knee Surg Sports Traumatol Arthrosc* 2005;13:695-698.
21. Khazen G, Khazen C. Tendoscopy in stage I posterior tibial tendon dysfunction. *Foot Ankle Clin* 2012;17:399-406.
22. Lui TH. Endoscopic assisted posterior tibial tendon reconstruction for stage 2 posterior tibial tendon insufficiency. *Knee Surg Sports Traumatol Arthrosc* 2007;15:1228-1234.
23. Hua Y, Chen S, Li Y, Wu Z. Arthroscopic treatment for posterior tibial tendon lesions with a posterior approach. *Knee Surg Sports Traumatol Arthrosc* 2015;23:879-883.
24. Monteagudo M, Maceira E. Posterior tibial tendoscopy. *Foot Ankle Clin* 2015;20:1-13.
25. Maffulli N, Kader D. Tendinopathy of tendo achillis. *J Bone Joint Surg [Br]* 2002;84-B:1-8.
26. Halasi T, Tállay A, Berkes I. Percutaneous Achilles tendon repair with and without endoscopic control. *Knee Surg Sports Traumatol Arthrosc* 2003;11:409-414.
27. Maquirriain J. Surgical treatment of chronic achilles tendinopathy: long-term results of the endoscopic technique. *J Foot Ankle Surg* 2013;52:451-455.
28. Pearce CJ, Carmichael J, Calder JD. Achilles tendinopathy and plantaris tendon release and division in the treatment of non-insertional Achilles tendinopathy. *Foot Ankle Surg* 2012;18:124-127.
29. Turgut A, Günel I, Maralcan G, Köse N, Göktürk E. Endoscopy, assisted percutaneous repair of the Achilles tendon ruptures: a cadaveric and clinical study. *Knee Surg Sports Traumatol Arthrosc* 2002;10:130-133.
30. Tang KL, Thermann H, Dai G, et al. Arthroscopically assisted percutaneous repair of fresh closed achilles tendon rupture by Kessler's suture. *Am J Sports Med* 2007;35:589-596.
31. Vega J, Cabestany JM, Golano P, Pérez-Carro L. Endoscopic treatment for chronic Achilles tendinopathy. *Foot Ankle Surg* 2008;14:204-210.
32. Thermann H, Benetos IS, Panelli C, Gavriilidis I, Feil S. Endoscopic treatment of chronic mid-portion Achilles tendinopathy: novel technique with short-term results. *Knee Surg Sports Traumatol Arthrosc* 2009;17:1264-1269.
33. Lui TH. Treatment of chronic noninsertional Achilles tendinopathy with endoscopic Achilles tendon debridement and flexor hallucis longus transfer. *Foot Ankle Spec* 2012;5:195-200.
34. Gossage W, Kohls-Gatzoulis J, Solan M. Endoscopic assisted repair of chronic achilles tendon rupture with flexor hallucis longus augmentation. *Foot Ankle Int* 2010;31:343-347.

Conflict of Interest: NIL
Source of Support: NIL

How to Cite this Article

Kini A, Munde A. Tendoscopy: A novel way to look at an Enigma; Indications, Technique & Results of managing tendon pathologies in foot and ankle. *Asian Journal of Arthroscopy* May-Aug 2018;3(2):24-29.